



Development of a high metastatic orthotopic model of human renal cell carcinoma in nude mice: benefits of fragment implantation compared to cell-suspension injection

Zili An¹, Ping Jiang¹, Xiaoen Wang¹, A.R. Moossa² & Robert M. Hoffman^{1,2}

¹AntiCancer, Inc., 7917 Ostrow St., San Diego, CA 92111, USA; ²Department of Surgery, University of California, 200 W. Arbor Dr., San Diego, CA 92103-8220, USA

Received 15 February 1999; accepted in revised form 25 March 1999

Key words: angiogenesis, metastasis, orthotopic fragment transplant, renal cancer

Abstract

In this study we compared the metastatic rate of human renal cell carcinoma SN12C in two orthotopic nude mouse models: surgical orthotopic implantation (SOI) of histologically intact tumor tissue and cellular orthotopic injection (COI) of cell suspensions in the kidney. The primary tumors resulting from SOI were larger and much more locally invasive than primary tumors resulting from COI. SOI generated higher metastatic expression than COI. The differences in metastatic rates in the involved organs (lung, liver, and mediastinal lymph nodes) were 2–3 fold higher in SOI compared to COI ($P < 0.05$). Median survival time in the SOI model was 40 days, which was significantly shorter than that of COI (68 days) ($P < 0.001$). Histological observation of the primary tumors from the SOI model demonstrated a much richer vascular network than the COI model. Lymph node and lung metastases were larger and more cellular in the SOI model compared to COI. We conclude that the tissue architecture of the implanted tumor tissue in the SOI model plays an important role in the initiation of primary tumor growth, invasion, and distant metastasis. This study directly demonstrates that the implantation of histologically intact tumor tissue orthotopically allows accurate expression of the clinical features of human renal cancer in nude mice. This model should be of value in cancer research and antimetastatic drug discovery for renal cancer, a currently very poorly responding malignancy.

Introduction

Human renal cell carcinoma, although a relatively uncommon type of cancer, has a very poor prognosis due to the lack of effective therapy. The prognosis of patients with renal cancer is determined mainly by the extent of metastasis, primarily in the lung [1].

The search for new anticancer agents and treatment modalities has been impeded by the limited availability of a clinically accurate mouse model, especially a highly metastatic model. Currently orthotopic implantation of human cancer into nude mice has already gained wide acceptance as the optimal method of creating more reliable models to study human cancer growth and progression *in vivo*, especially metastasis. Orthotopic implantation, as opposed to heterotopic implantation, allows more accurate expression of the biological nature of the original human tumor, including growth rate, morphology and metastasis [2–4].

Several laboratories have established metastatic nude mice models of human renal cell carcinoma by injecting tumor cell suspensions into the renal subcapsule of the nude mice [1, 5–8]. Cell leakage can cause experimental variability

in this technique [6, 26]. In addition, mechanical and/or enzyme processing of tumor cells disrupts inter-cell communication and the natural tumor-stromal structure. Thus, cell suspensions do not have the native three-dimensional tissue architecture, which seems important for the full expression of their spontaneous metastatic potential as seen in direct comparisons of orthotopic implantation of cell suspensions and intact tissue [18, 20].

Over the past eight years in our laboratory, we have established novel methods of surgical orthotopic implantation (SOI) of histologically intact human tumor tissue of various types in nude mice [9–14, 17–20]. The SOI models demonstrated extensive metastatic potential. In this study we applied the principle of SOI to human renal cell carcinoma. A head-to-head comparison of tumor growth, invasion, metastasis, and survival was made between the SOI model and the cellular orthotopic injection (COI) of cell suspensions. The results demonstrate that the intact tumor tissue implantation is significantly advantageous over cell suspension injection for expression of malignancy, metastasis, and shortened survival.

Materials and methods

Animals

Athymic nu/nu Balb/c mice (Charles River Laboratories, Wilmington, MA), 4–5 weeks old, were used in the study. They were maintained in a specific pathogen-free environment in compliance with USPHS guidelines governing the care and maintenance of experimental animals. All animal studies were conducted in accordance with the principles and procedures outlined in the National Institutes of Health Guide for the Care and Use of Laboratory Animals under assurance number A3873-1. Mice were fed with autoclaved laboratory rodent diet (Tecklad LM-485, Western Research Products, Orange, CA).

Cell and cell culture conditions

Human renal cell carcinoma cell line SN12C was first established in culture from a primary renal cell carcinoma from a 43-year-old man [4]. The cells used in this study were from cryopreserved vials. Prior to implantation, frozen cells were thawed and passed twice in RPMI 1640 culture medium (Bio-Whittaker, Walkersville, MD) supplemented with 10% fetal bovine serum, nonessential amino acids, L-glutamine, sodium pyruvate, sodium bicarbonate, glucose, and two-fold vitamin solution (GIBCO BRL, Grand Island, NY). 100 μ /ml of penicillin and 100 μ g/ml streptomycin were added in the culture medium. The cells were cultured in a humidified atmosphere containing 5% CO₂ and 95% air. All cells were examined and found to be free of *Mycoplasma* and viruses prior to use (Microbiological Associates, Bethesda, MD).

Cells for implantation were harvested from subconfluent cultures with a solution of 0.25% trypsin and 0.02% EDTA, collected and washed twice in Hanks balanced salt solution (HBSS) and resuspended in HBSS to give the appropriate volume for orthotopic and subcutaneous injection. Only single-cell suspensions with viability of more than 90% as assessed by trypan blue dye exclusion were used for injection.

Renal subcapsule cellular orthotopic injection (COI) of cell suspensions

Mice were anesthetized with isoflurane (Ohameda Caribe Inc., Guayama, PR). A small incision was made along the left flank of the mouse. The kidney was exposed with a small retractor. A 27-gauge needle was used for the tumor cell injection. The needle was inserted into the lower pole of the kidney and advanced until its point reached just below the renal subcapsule. Two million viable SN12C tumor cells were injected in a volume of 0.05 ml HBSS. Visible bulla formation between the renal parenchyma and the capsule was the criterion for a successful injection. The needle was then carefully removed and animals checked for local bleeding and extra-renal leakage of tumor cell suspension. If leakage or severe bleeding was found, the animal was eliminated. Reopening the abdomen was performed to check the existing bulla under the renal capsule after the animals recovered

from anesthesia and started to move. In this study, only three mice were found to have leakage and one mouse had bleeding. They were all replaced with new animals. After the injection, the kidney was wrapped with the surrounding soft tissue with an 8-0 nylon suture. The abdominal wall was closed with a 6-0 silk suture. All procedures were carried out under a 5X-dissection microscope.

Subcutaneous tumor growth

Cells suspended as above were injected subcutaneously at 2×10^6 per nude mouse. The purpose of growing the subcutaneous tumor was for stock tumor tissue to be used in SOI. When the tumors were growing in the log phase, they were harvested. The periphery of the tumors was collected following removal of necrotic and less viable tissue near the center of the tumor. Tumor tissue was cut into small pieces of one cubic millimeter each, which were mixed thoroughly during implantation to insure that all the mice were transplanted with equally viable tissue. The use of stock tumor tissue for SOI grown at the subcutaneous site was for experimental convenience and for tumor tissue of high malignant potential when transplanted by SOI in the renal capsule.

Renal subcapsule surgical orthotopic implantation (SOI) of tumor fragments

Mice were anesthetized by isoflurane and positioned laterally. A small incision was made along the left flank of the mice. The kidney was exposed with a small retractor. A small cut was made on the renal subcapsule. One piece of tumor tissue was inserted into the capsule. The cut was covered with surrounding soft tissue using an 8-0 nylon suture. The abdomen was closed with a 6-0 silk suture. All procedures were carried out under a 5X-dissection microscope.

Evaluation of tumor growth and metastasis

All mice from both transplantation procedures were closely observed and allowed to live through their natural course of disease after tumor cell implantation. At time of death, one fragment of the primary tumor and two fragments from each lobe of the lung and the liver as well as all detectable mediastinal lymph nodes were sampled and immersed in 10% formalin for fixation. The sampled tissues were dehydrated, embedded, sectioned and then stained with standard hematoxylin and eosin staining procedure for microscopic examination.

Statistical analysis

The incidence of survival at defined time points and the incidence of metastasis in both cell injection and tissue implantation were analyzed using the Fisher Exact test. The median survival was analyzed using the Wilcoxon Rank-Sum test.

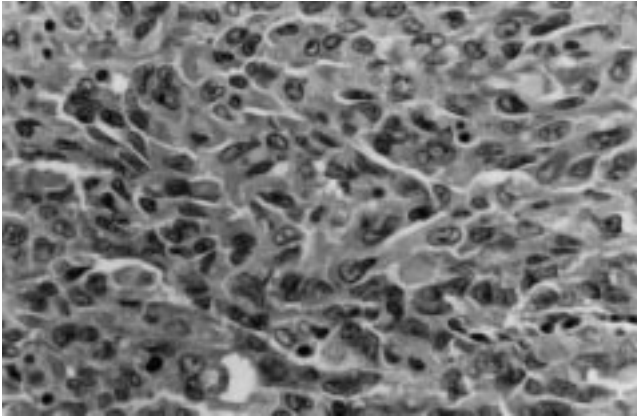


Figure 1. Histology of the primary tumor from the SOI model. Note the bizarre nuclei and polygonal shapes of the cells.

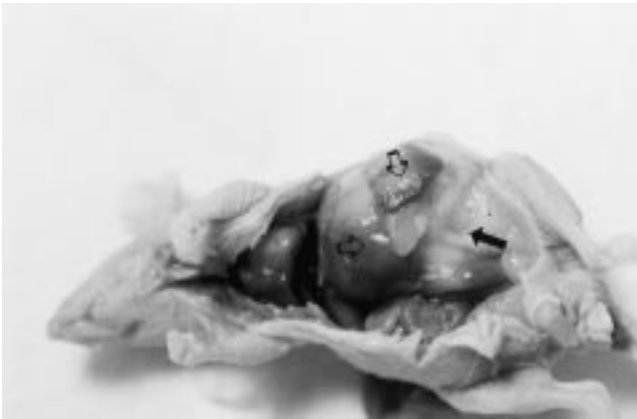

Figure 2. Gross picture of primary tumor in the SOI model. Note that the liver and the spleen (hollow arrows) are adhered to by the primary tumor (black arrows).

Results

Primary tumor growth

The human renal carcinoma cell line SN12C implanted by SOI with intact tumor tissue grew very aggressively in the renal subcapsule of nude mice. The take rate was 100%, compared with 75% for COI. In the SOI and COI models, the tumor cells were polygonal and contained large bizarre nuclei (Figure 1). In the SOI model, all primary tumors destroyed most of the renal parenchyma and disfigured the abdomen (Figure 2). The local invasion was extensive, with the abdominal wall, the pancreas, the spleen, the liver and a large portion of the intestine adhering to the primary tumor (Figure 2). In contrast, COI generated relatively small primary tumors with less severe local invasion, i.e. the spleen and the liver were usually spared (Figure 3).

Vascularity of the primary tumor

Close examination of the histology of the primary tumor revealed that the primary tumors in the SOI model were rich in blood vessels. In contrast in the COI model, blood vessels were sparse (Figure 4).

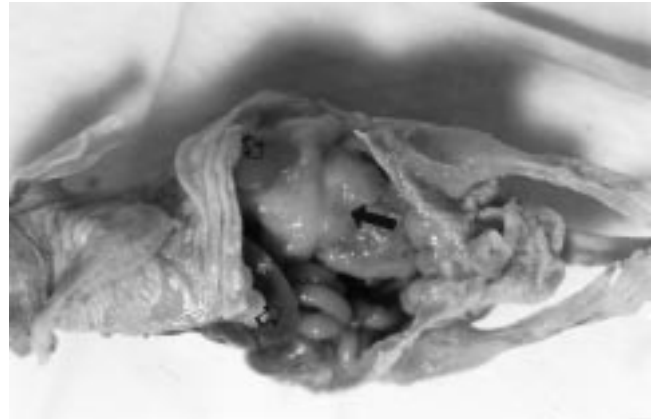
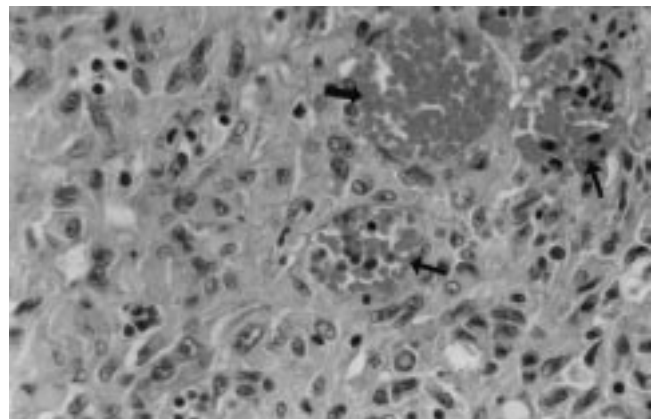
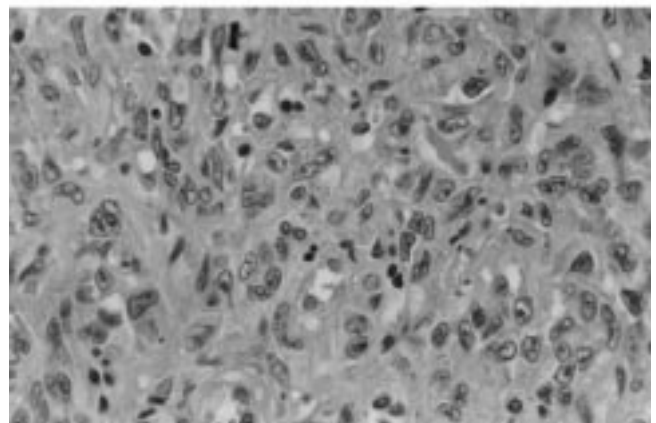


Figure 3. Gross picture of the primary tumor in the COI model. The liver and the spleen (hollow arrows) are free of invasion from the tumor (black arrows).



A



B

Figure 4. A. Photomicrograph shows the rich vasculature (arrows) in the primary tumor of the SOI model. B. Photomicrograph shows apparent lack of vasculature in the COI model.

Systemic metastasis

Both models demonstrated metastases in the lung, the liver and the mediastinal lymph nodes. However, the metastatic rate for lung, liver and mediastinal lymph nodes was 2–3 fold higher in SOI compared to COI. This difference in incidence was statistically significant ($P < 0.05$ by the Fisher-Exact test) (Table 1).

Table 1. Comparison of metastatic and survival rates of human renal carcinoma SN12C in SOI and COI models of renal carcinoma

Orthotopic model	Take rate	Median survival*	Site and incidence of metastasis**		
			Lung	Liver	MLN***
Tissue implant (SOI)	100%	40 days	12/20	8/20	19/20
Cell injection (COI)	75%	68 days	4/15	2/15	7/15

* $P < 0.001$ by the Wilcoxon Rank-Sum test. ** $P < 0.05$ when the incidence of metastasis in all the three organs listed was compared between the two models by the Fisher Exact Test. ***MLN – mediastinal lymph node.

Mediastinal lymph nodes were usually exceedingly enlarged upon autopsy of mice with the SOI model. Some modified lymph nodes were as large as 0.5 cm. Microscopically, widespread infiltration of tumor cells was found in the subcapsular, the cortical, and medullary areas. Some tumor cells formed large nests that totally replaced the nodal parenchyma. In many of the nodes analyzed, tumor cells occupied the whole node and the lymphatic cells could be barely seen. In contrast in the COI model, lymph node metastases were relatively small and constricted. Clusters of metastatic cells were spotted within the nodes but did not form large nests and seldom totally replaced large areas of nodal parenchyma (Figure 5).

The lung metastases were disseminated in the SOI models. Large nests of tumor cells usually squeezed the nearby alveoli. In contrast, in the COI model, lung metastases were small and less diffuse (Figure 6).

Liver metastases were observed in both the SOI and COI models (Table 1). There was a significant higher liver metastatic rate in the SOI model compared to the COI. However, no morphological differences in the liver metastases lesions were observed (Figure 7).

Survival of animals

The SOI model demonstrated a shorter median survival (40 days) compared to the COI model (68 days) ($P < 0.001$ by the Wilcoxon Rank-Sum test) (Table 1 and Figure 8). When all the animals in the SOI group had died, 80% of the mice in COI group were still alive ($P < 0.001$ by the Fisher Exact Test). When the metastatic rates in different organs were taken into account, it was probable that the SOI model succumbed mostly due to distant metastases while in the COI model death was due to primary tumor burden.

Discussion

The purpose of this study was to determine if surgical orthotopic implantation (SOI) of histologically intact tumor tissue could allow higher expression of the biological nature of a human renal cell carcinoma in nude mice than cellular orthotopic injection (COI) of cell suspensions.

The technique of using histologically intact tumor tissue to construct orthotopic models of human cancer in nude

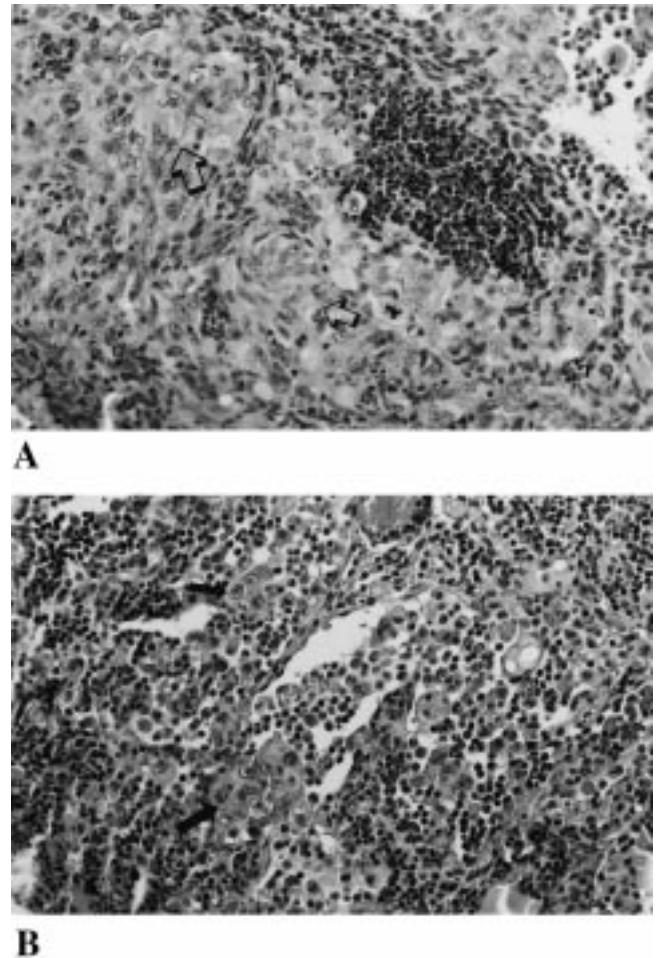
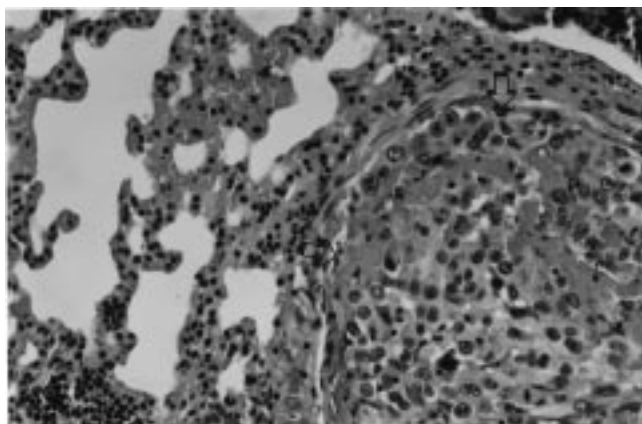
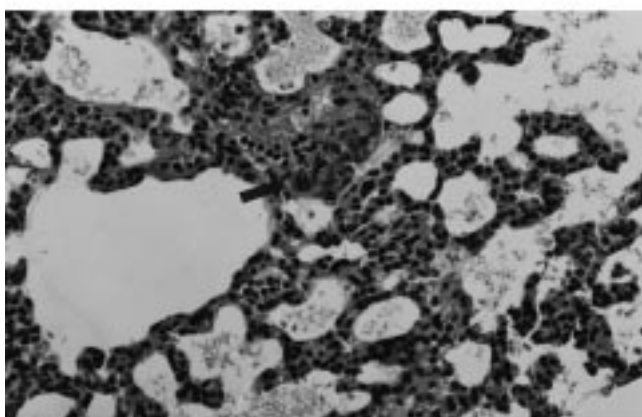


Figure 5. A. Lymph node from SOI model. Note the large tumor nests (arrows). B. Lymph node from the COI model showing metastatic cells are sparse and do not form large nests (arrows).

mice was based on the idea that the supportive stromal tissue architecture in a tumor mass plays a role in the growth and spread of human cancer. It has been shown that the proliferation of tumor cells implanted in nude mice was preceded by the penetration of host stromal cells into the tumor [15, 16]. The supportive stromal cells maintain the three-dimensional architecture of the tumor and allow growth factors, angiogenic factors and other stimulating factors to interact between the tumor cells and stroma. Previous studies with other human cancer types support these ideas [17–21].



A



B

Figure 6. A. Lung metastasis in SOI model containing large nests of tumor cells (arrows). B. Lung metastasis in COI model containing small nests of tumor cells (arrows).

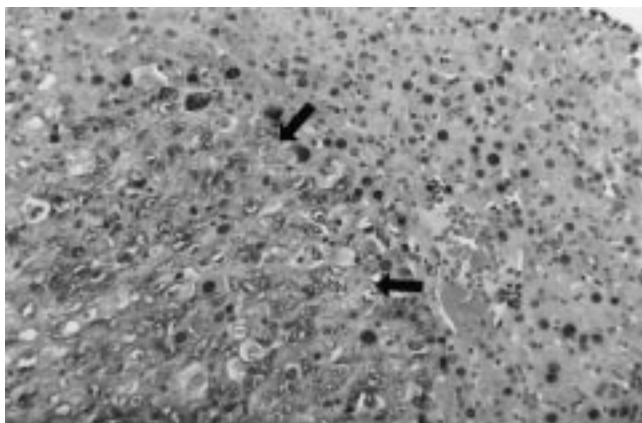


Figure 7. Liver metastasis in the SOI model (arrows).

Since the first isolation of the SN12C cell line [8], several laboratories have reported the metastatic nature of this human renal cell carcinoma in nude mice. Those studies were all conducted using the COI model [1, 5–26]. This is the first report on SOI of this line into the kidney of nude mice.

Since metastatic properties of a cancer cell line such as SN12C may change between laboratories or even in a single laboratory [8, 26] and make the results difficult to compare, we conducted a head-to-head study. Both cell suspensions

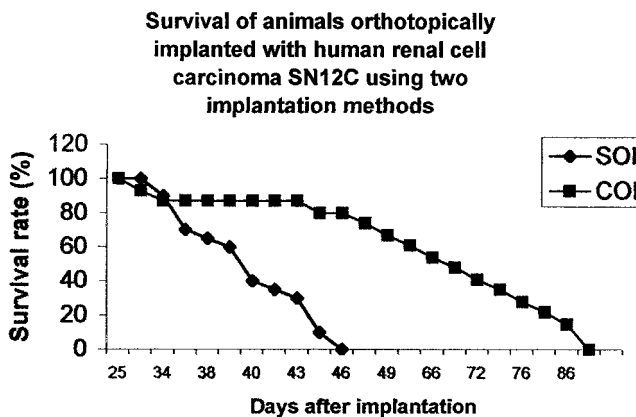


Figure 8. Survival curve of SOI and COI models of human renal cell carcinoma SN12C.

and tumor tissue of SN12C were derived from the same *in vitro* passage. The tumor tissue implanted orthotopically was harvested from a subcutaneous tumor. The tumor tissue fragments used for SOI were 1 mm³ which we estimated contained the same amount of viable cells, 2 × 10⁶, that was used for COI in each mouse.

Our results indicated SOI expressed significantly more metastasis as compared with orthotopic injection of cell suspensions. The survival of SOI mice was significantly shorter than that of the COI mice, indicating much earlier and more aggressive metastases in the SOI model

Tumor cells are thought to grow better in injured tissue than healthy ones. The SOI procedure caused only minimal trauma to the renal parenchyma, since only a small cut was made in the capsule and the renal parenchyma was not injured. In contrast, in COI, a syringe needle was used to penetrate the renal parenchyma to reach the subcapsule space, where tumor cells were injected. In both SOI and COI, the abdomen was opened to expose the kidney. Therefore, the lesser tumor growth and extent of metastasis of COI compared to SOI is not explainable by less surgical trauma.

The primary tumors from SOI were richer in blood vessels than those from COI, suggesting the three-dimensional tumor-stromal architecture of implanted tumor tissue might function in tumor angiogenesis. The SOI model resembled the primary renal tumor in the patient, which is also rich in blood vessels.

A recent study by Cowen *et al.* showed that the metastatic lesions resulting from SOI of a mouse colon adenocarcinoma had rich and functional networks of blood vessels. The vascularity was much different from the organ deposits of this tumor after *i.v.* injection of cell suspensions, which had poor vascular development [21]. This result agreed with our suggestion as to the function of three-dimensional tumor-stromal architecture in histologically intact tissue to promote tumor growth and progression, including tumor angiogenesis. It is believed that there are two stages in the development of a tumor: the prevascular stage and the vascular stage. The vascular stage is usually demarcated by rapid tumor growth and the potential for metastasis [22, 23]. Therefore earlier metastasis usually indicates faster and earlier angiogenesis. There is also evidence that intensity of an-

giogenesis correlates well with the rate of metastasis [24]. Future studies will focus on new vessel formation in the primary and metastatic tumors in the SOI compared to the COI models to confirm the hypothesis of the relationship of angiogenesis to increased metastatic potential in the SOI models. These studies will involve precise immunohistochemical staining for the presence of microvasculature in the tumors and metastases developed in the SOI and COI models.

In the present study, early death was thought to be mainly due to early distant metastasis and the high metastatic rates in the SOI model.

The organ microenvironment can have a profound influence on the growth and expression of metastatic potential of implanted human tumors [2–4, 8, 25, 26]. The SOI model allows optimal expression of the biological nature of the implanted tumor, including angiogenesis, primary tumor growth, and distant metastases. This study demonstrated the quantitative and qualitative differences in the resulting primary tumor growth, distant metastases, and survival of the SOI model, compared to the COI model.

SOI of histologically intact human tumor tissue provides a more suitable microenvironment for the tumor. The SOI model developed in this study thus provides an accurate model of renal carcinoma to investigate mechanisms of metastasis and for drug discovery and development. The present study has revealed the high metastatic potential of human renal carcinoma SN12C. SOI models of cell lines from other tumor types have also revealed a high metastatic potential [9–14, 17–20] that was not apparent in other model types. It is, therefore, possible that many tumor cell lines will be found to have interesting and important metastatic properties when investigated in SOI models. The SOI models should make an important contribution to our understanding of the mechanisms and therapy of metastasis of many types of cancer.

Acknowledgements

This study was supported in part by U.S. National Cancer Institute Grant R44 CA53963.

References

- Marutsuka K, Hasui Y, Asada Y et al. Effects of suramin on metastatic ability, proliferation, and production of urokinase-type plasminogen activator and plasminogen activator inhibitor type 2 in human renal cell carcinoma cell line SN12C-PM6. *Clin Exp Metastasis* 1995; 13: 116–22.
- Morikawa K, Walker SM, Jessup JM, Fidler IJ. *In vivo* selection of highly metastatic cells from surgical specimens of different primary human colon carcinoma implanted into nude mice. *Cancer Res* 1988; 48: 1943–8.
- Nakajima M, Morikawa K, Fabra A et al. Influence of organ microenvironment on extracellular matrix degradative activity and metastasis of human colon carcinoma cells. *J Natl Cancer Inst* 1990; 82: 1890–8.
- Vieweg J, Heston WDW, Gilboa E, Fair WR. An experimental model simulating local recurrence and pelvic lymph node metastasis following orthotopic induction of prostate cancer. *Prostate* 1994; 24: 291–8.
- Singh RK, Bucana CD, Gutman M et al. Organ site-dependent expression of basic fibroblast growth factor in human renal cell carcinoma cells. *Am J Pathol* 1994; 145: 365–74.
- Naito S, Walker SM, von Eschenbach AC, Fidler IJ. Evidence for metastasis heterogeneity of human renal cell carcinoma. *Anticancer Res* 1988; 8: 1163–7.
- Burgers JK, Marshall FF, Isaacs JT. Enhanced anti-tumor effects of recombinant human tumor necrosis factor plus VP-16 on metastatic renal cell carcinoma in a xenograft model. *J Urol* 1989; 142: 160–4.
- Naito S, von Eschenbach AC, Fidler IJ. Different growth pattern and biologic behavior of human renal cell carcinoma implanted into different organs of nude mice. *JNCI* 1987; 78: 377–85.
- Fu X, Besterman JM, Monosov A and Hoffman RM. Models of human metastatic colon cancer in nude mice orthotopically constructed by using histologically intact patient specimens. *Proc Natl Acad Sci USA* 1991; 88: 9345–9.
- Fu X, Guadagni F and Hoffman RM. A metastatic nude-mouse model of human pancreatic cancer constructed orthotopically from histologically intact patient specimens. *Proc Natl Acad Sci USA* 1992; 89: 5645–9.
- Hoffman RM. Patient-like models of human cancer in mice. *Current Perspectives Molecular Cellular Oncol* 1992; 1(B): 311–26.
- Wang X, Fu X, Hoffman RM. A new patient-like metastatic model of human lung cancer constructed orthotopically with intact tissue via thoractomy in immunodeficient mice. *Int J Cancer* 1992; 51: 992–5.
- Astoul P, Colt HG, Wang X, Hoffman RM. Metastatic human pleural ovarian cancer model constructed by orthotopic implantation of fresh histologically intact patient carcinoma in nude mice. *Anticancer Res* 1993; 13: 1999–2002.
- An Z, Wang X, Kubota T et al. A clinical nude mouse metastatic model for highly malignant human pancreatic cancer. *Anticancer Res* 1996; 16: 627–32.
- Kopf-Maier P, Jackel M. Proliferation behavior of xenografted human tumors: A flow cytometric study. *Anticancer Res* 1988; 8: 1355–60.
- Kopf-Maier P. Dying and regeneration of human tumor cells after heterotransplantation to athymic mice. *Histol Histopathol* 1986; 1: 383–90.
- An Z, Wang X, Geller J et al. Surgical orthotopic implantation allows high lung and lymph node metastatic expression of human prostate carcinoma cell line PC-3 in nude mice. *Prostate* 1998; 34: 169–74.
- Fu X, Hoffman RM. Human RT-4 bladder carcinoma is highly metastatic in nude mice and comparable to rasH-transformed RT-4 when orthotopically onplanted as histologically intact tissue. *Int J Cancer* 1992; 51: 989–91.
- Fu X, Theodorescu D, Kerbel RS, Hoffman RM. Extensive multiorgan metastasis following orthotopic onplantation of histologically-intact human bladder carcinoma tissue in nude mice. *Int J Cancer* 1991; 49: 938–9.
- Furukawa T, Fu X, Kubota T et al. Nude mouse metastatic models of human stomach cancer constructed using orthotopic implantation of histologically intact tissue. *Cancer Res* 1993; 53: 1204–8.
- Cowen SE, Bibby MC, Double JA. Characterization of the vasculature within a murine adenocarcinoma growing in different sites to evaluate the potential of vascular therapies. *Acta Oncologica* 1995; 34: 357–60.
- Folkman J, Watson K, Ingber D, Hanahan D. Induction of angiogenesis during the transition from hyperplasia to neoplasia. *Nature* 1989; 339: 58–61.
- Folkman J. Angiogenesis. In: Verstraete M, Vermynen J, Lijnan R, Arnout J (eds) *Thrombosis and haemostasis*. Leuven: Leuven University Press, 1987; 583–96.
- Weidner N, Semple JP, Welch WR, Folkman J. Tumor angiogenesis and metastasis—correlation in invasive breast carcinoma. *N Engl J Med* 324 1991; 1–8.
- Togo S, Shimada H, Kubota T, Moossa AR, Hoffman RM. Host organ specifically determines cancer progression. *Cancer Res*. 1995; 55: 681–4.
- Naito S, von Eschenbach AC, Giavazzi R, Fidler IJ. Growth and metastasis of tumor cells isolated from a human renal cell carcinoma implanted into different organs of nude mice. *Cancer Res* 1986; 46: 4109–15.