

Human Ovarian Carcinoma Metastatic Models Constructed in Nude Mice by Orthotopic Transplantation of Histologically-Intact Patient Specimens

XINYU FU¹, and ROBERT M. HOFFMAN^{1,2}

¹AntiCancer, Inc., 5325 Metro Street, San Diego, CA 92110

²Laboratory of Cancer Biology, Department of Pediatrics, 0609F University of California, San Diego, La Jolla, CA 92093-0609, U.S.A.

Abstract. We report here the first orthotopic transplant model for human ovarian cancer. Histologically-intact patient specimens of ovarian cancer were transplanted by microsurgical techniques under the capsule of the nude mouse ovary. The human tumors grew locally and gave rise to a patient-like metastatic pattern including the parietal peritoneum, colon, omentum, and ascites. The orthotopic model described here should be useful for evaluating new therapeutics and diagnostics for ovarian cancer.

There have been many attempts to develop models of human ovarian carcinoma for use in understanding the biology of the disease as well as for testing of standard and experimental treatments. The first *in vivo* models included human ovarian carcinomas implanted subcutaneously in nude mice which usually do not metastasize (1-4). Another model was subsequently developed which was constructed by intraperitoneal injection of the cell line NIH: OVCAR-3^{m(cig+)} into nude mice. This cell line was derived from a tumor resistant to drugs in the patient and develops intraabdominal carcinomas in nude mice, as well as ascites (5). The cell line was selected for growth in nude mice and in agarose (5). This model has been shown to be useful for evaluation of certain therapeutic regimens (6). Ward *et al* (7) intraperitoneally injected a slurry derived from patient specimens into nude mice which resulted in intraabdominal carcinomas, but distant metastases were rare. Massazza *et al* (8) intraperitoneally injected into nude mice either patient ascites from ovarian tumors or cell suspensions derived from human ovarian cancers that resulted in ascites growing in the nude mice. However, until now, no model of ovarian cancer has been developed that

reflects the clinical picture of local growth initiating in the ovary with subsequent extension and metastasis from the site.

In this light, we wished to develop ovarian carcinoma models in nude mice that could be constructed directly from essentially any patient and not depend on selecting a cell line or making cell suspensions, and whose growth and metastasis originated from the ovary itself. In order to achieve this goal, we orthotopically transplanted human ovarian tumor specimens to the nude-mouse ovary with resulting local growth and a metastatic pattern reflecting the clinical picture as described in this report.

To construct such models of ovarian cancer, we utilized techniques we developed for orthotopically implanting in nude and severe combined immunodeficient (SCID) mice histologically intact human specimens of colon cancer (9,10), bladder cancer (11,12), pancreatic cancer (13), lung cancer (14-16), prostate cancer (17), and stomach cancer (18), which resulted in local growth and metastases reflecting the clinical situation. In at least bladder cancer (11,12), stomach cancer (18), and lung cancer (14-16), intact tissue orthotopic transplants seem to result in considerably more metastatic potential than orthotopic injection of cell suspensions. The construction of such orthotopic models with actual patient specimens of ovarian cancer which are histologically intact is the subject of this report.

Materials and Methods

SCID and nude mice were anesthetized by isoflurane (Forane) inhalation. A midline incision was made in the lower abdomen of the nude mouse, and the peritoneum was opened. One side of the ovary of the nude mouse was exposed. The capsule of the ovary was opened and intact pieces of human ovarian tumor tissue were transplanted into the capsule. The capsule was closed with an 8-0 surgical suture. In this way, at maximum two pieces of tumor tissue can be transplanted orthotopically. In order to transplant more tissue orthotopically, we also carried out the onplantation method, *i.e.* after the opening of the ovarian capsule, five to six pieces of tumor tissue were transplanted on the mouse ovary by an 8-0 surgical suture with the ovarian capsule left open. After orthotopic transplantation, the nude mouse abdomen was closed with 6-0 surgical sutures on one layer. The procedure takes approximately 10 minutes.

Correspondence to: Robert M. Hoffman, Ph.D. FAX: (619) 534-6032 or (619)299-2435.

Key Words: Ovarian carcinoma, human, metastatic models, nude mice, orthotopic transplantation.

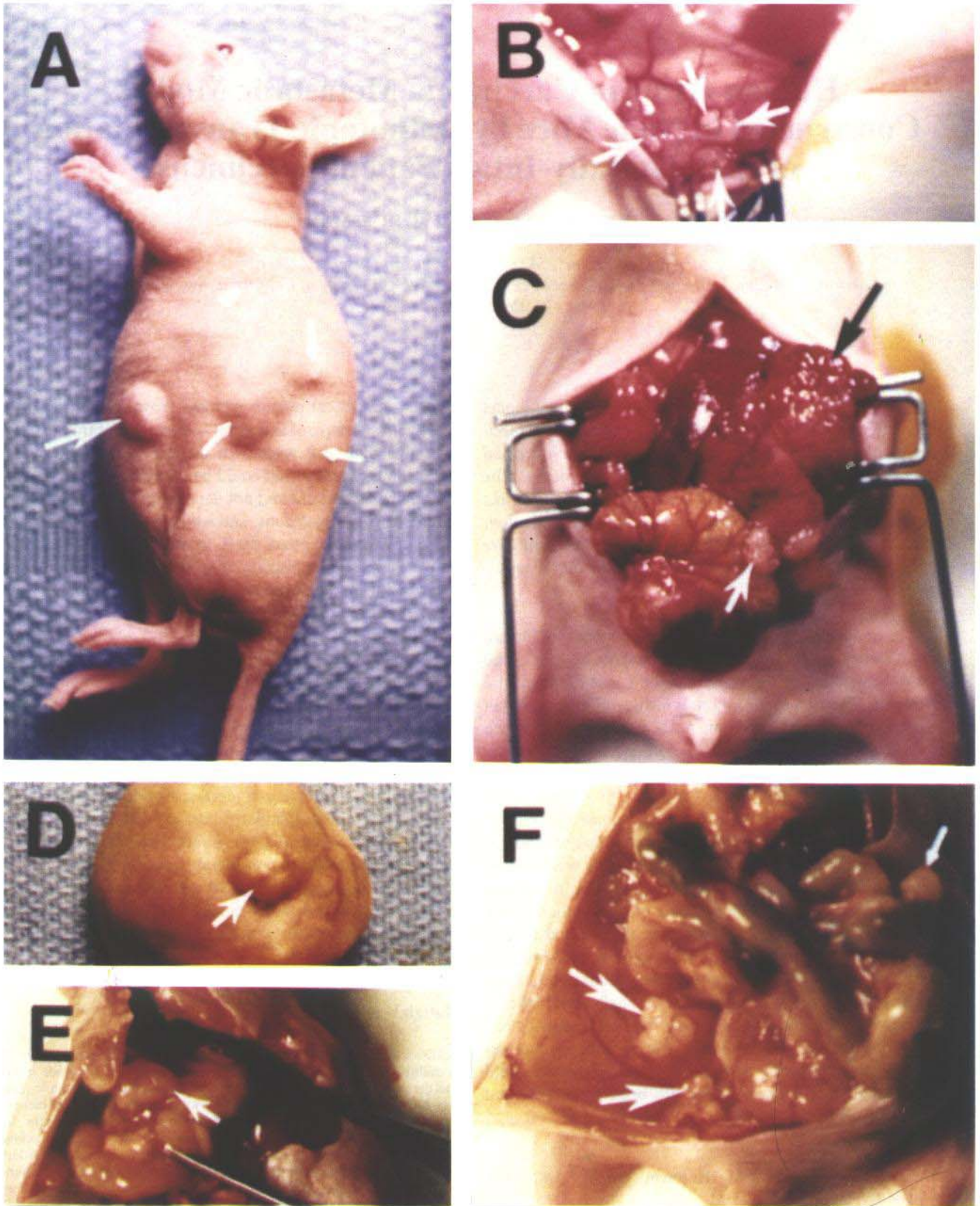


Figure 1

Table I. Growth and metastases of human ovarian carcinomas after orthotopic transplantation as intact tissue in nude mice.

Case No.	Stage/Grade in patient	Number of mice with tumors after transplantation/ number of mice transplanted	Growth and metastases in nude mice
1943	Stage II Poorly differentiated metastatic adenocarcinoma	2/3	Local growth
2443	Stage IV Poorly differentiated adenocarcinoma, including small-bowel and omentum metastasis	4/4	Local growth, extensive metastasis, to peritoneum, colon, and omentum

Results and Discussion

Five cases of human ovarian cancer were transplanted into nude mice (Table I), two of which gave rise to tumors. In the first case with patient specimen #1943, the largest growth was an encapsulated cyst, measuring 33×23 mm with watery fluid. No rupture or intraperitoneal seeding was observed. This tumor grew with a cystadenocarcinoma growth pattern. In the second case (Figure 1) with patient specimen #2443, extensive solid primary tumor growth was observed along with ascites with extensive metastasis to the colon, omentum and parietal peritoneum of two of the nude mice. It should be noted that in the patient there was also metastasis to the bowel and omentum.

As can be seen from Table I, the orthotopically-transplanted tumors in the mice resembled the tumors in the patients.

The nude mouse models of human ovarian carcinoma described in this report, unlike previous models, reflect the clinical picture and have the following advantages over previous models:

- 1) They can be constructed directly from patient tumor specimens.
- 2) The tumors grow locally in the ovary.
- 3) The tumors can metastasize from the ovary to the peritoneal wall and to critical organs such as the colon, and the omentum all of which reflects the clinical situation.

The approach to the construction of models of human ovarian cancer reflecting the clinical picture described here should be of eventual use to evaluate experimental treatment of ovarian cancer and for modeling of individual patient tumors, which heretofore was not possible. The models described here should facilitate treatment testing and decision making.

Acknowledgements

This work was supported by U.S. National Cancer Institute Small Business Innovation Research Grant R43 CA53963. We thank Dr. Tyler Youngkin, Mercy Hospital and Medical Center, and Drs. Gerald Bordin and Max Elliott of Scripps Clinic for tumor specimens. We thank Ms. Polly Jayne Pomeroy for expert word processing of the manuscript.

Figure 1. Orthotopic transplantation of human ovarian cancer case #2443 to nude mice.

1A. Human ovarian cancer metastasized to nude mouse abdominal wall after being orthotopically transplanted to nude mouse ovary (big arrow). Tumor masses can also be noticed throughout the abdominal area (small arrows).

1B. Human ovarian cancer seeding growth on parietal peritoneum in nude mouse after being transplanted orthotopically to nude mouse ovary (arrows).

1C. Human ovarian cancer grown on nude mouse ovary after orthotopic transplantation. Black arrow indicates tumor growth on nude-mouse ovary. White arrow indicates metastasis to the nude-mouse colon.

1D. Human ovarian cancer grown on nude mouse ovary after orthotopic transplantation. Extensive tumor growth, intraperitoneal seeding and ascites occurred. Arrow indicates abdominal wall metastasis.

1E. Seeding growth of human ovarian cancer on the omentum (arrow) of the same mouse as in 1D after orthotopic transplantation.

1F. Metastasis of human ovarian cancer on the nude mouse colon of the same mouse as in 1D (small arrow) and to the retroperitoneum, (big arrows).

References

- 1 Davy M, Mossige J and Johannesson J: Heterologous growth of human ovarian cancer. A new in vivo testing system. *Acta Obstet Gynecol Scand* 56: 55-59, 1977.
- 2 Kullander S, Rausing A and Tropé C: Human ovarian tumor heterotransplanted to «nude» mice. *Acta Obstet Gynecol Scand* 57: 149-159, 1978.
- 3 Taetle R, Howell SB, Giuliani F, Koziol J and Koessler A: Comparison of the activity of doxorubicin analogues using colony forming assays and human xenografts. *Cancer* 50: 1455-1461, 1982.
- 4 Sawada M, Terada N, Wada A, Mori Y, Yamasaki M, Saga T and Endo K: Estrogen- and androgen-responsive growth of human ovarian carcinoma heterotransplanted into nude mice. *Int J Cancer* 45: 359-363, 1990.
- 5 Hamilton T, Young R, Louie K, Behrens B, McKoy W, Grotzinger R and Ozols RF: Characterization of a xenograft model of human ovarian carcinoma which produces ascites and intraabdominal carcinomatosis in mice. *Cancer Res* 44: 5286-5290, 1984.
- 6 Ozols R, Louie K, Plowman J, Behrens B, Fine R, Dykes D and Hamilton T: Enhanced melphalan cytotoxicity in human ovarian cancer *in vitro* and in tumor-bearing nude mice by buthionine sulfoximine depletion of glutathione. *Biochem Pharmacol* 36: 147-153, 1987.
- 7 Ward B, Wallace K, Shepherd J and Balkwill F: Intraperitoneal xenografts of human epithelial ovarian cancer in nude mice. *Cancer Res* 47: 2662-2667, 1987.
- 8 Massazza G, Tomasoni A, Lucchini V, Allavena P, Erba E, Colombo N, Mantovani A, D'Incalci M, Mangioni C and Giavazzi R: Intraperitoneal and subcutaneous xenografts of human ovarian carcinoma in nude mice and their potential in experimental therapy. *Int J Cancer* 44: 494-500, 1989.
- 9 Fu X, Besterman JM, Monosov A and Hoffman RM: Models of human metastatic colon cancer in nude mice orthotopically constructed by using histologically-intact patient specimens. *Proc Natl Acad Sci USA* 88: 9345-9349, 1991.
- 10 Fu X, Herrera H, Kubota T and Hoffman RM: Extensive liver metastasis from human colon cancer in nude and scid mice after orthotopic onplantation of histologically-intact human colon carcinoma tissue. *Anticancer Res* 12: 1395-1398, 1992.
- 11 Fu X, Theodorescu D, Kerbal RS and Hoffman RM: Extensive multi-organ metastasis following orthotopic onplantation of histologically-intact human bladder carcinoma tissue in nude mice. *Int J Cancer* 49: 938-939, 1991.
- 12 Fu X and Hoffman RM: Human RT-4 bladder carcinoma is highly metastatic in nude mice and comparable to *ras*H-transformed RT-4 when orthotopically onplanted as histologically-intact tissue. *Int J Cancer* 51: 989-991, 1992.
- 13 Fu X, Guadagni F and Hoffman RM: A metastatic nude-mouse model of human pancreatic cancer constructed orthotopically from histologically-intact patient specimens. *Proc Natl Acad Sci USA* 89: 5645-5649, 1992.
- 14 Wang X, Fu X and Hoffman RM: A new patient-like metastatic model of human lung cancer constructed orthotopically with intact tissue via thoracotomy in immunodeficient mice. *Int J Cancer* 51: 992-995, 1992.
- 15 Wang X, Fu X and Hoffman RM: A new patient-like metastatic model of human small cell lung cancer constructed orthotopically with intact tissue via thoracotomy in immunodeficient mice. *Anticancer Res* 12: 1407-1402, 1992.
- 16 Wang X, Fu X and Hoffman RM: A patient-like metastasizing model of human lung adenocarcinoma constructed via thoracotomy in nude mice. *Anticancer Res* 12: 1399-1402, 1992.
- 17 Fu X, Herrera H and Hoffman RM: Orthotopic growth and metastasis of human prostate carcinoma in nude mice after transplantation of histologically-intact tissue. *Int J Cancer* 52: 987-990, 1992.
- 18 Furukawa T, Fu X, Kubota T, Watanabe M, Kitajima M and Hoffman RM: Nude mouse metastatic models of human stomach cancer constructed using orthotopic implantation of histologically-intact tissue. *Cancer Research*, In Press.

Received October 27, 1992
Accepted December 18, 1992