

## ORIGINAL PAPER

Fan-Xian Sun · Zhao-You Tang · Kang-Da Liu · Qiong Xue  
Dong-Mei Gao · Ye-Qin Yu · Xin-Da Zhou · Zeng-Chen Ma

## Metastatic models of human liver cancer in nude mice orthotopically constructed by using histologically intact patient specimens

Received: 25 September 1995/Accepted: 1 November 1995

**Abstract** In this study of orthotopic implantation of histologically intact surgical specimens, the authors constructed metastatic models of human hepatocellular carcinoma (HCC) in nude mice. Histologically intact human liver cancer specimens, derived from patients, were implanted directly into the liver of nude mice, and their orthotopic growth and metastases were observed. The transplantability and metastatic rate of two specimen groups (primary and metastatic lesions) were analysed.  $\alpha$ -Fetoprotein (AFP) was also determined in transplanted tumours by an immunohistochemical method. Orthotopic growth was observed in 14 of 30 transplanted specimens and formation of metastases in 7 cases, which exhibited the variety of clinical behaviours seen in patients with HCC. These behaviours included local growth, regional invasion, spontaneous intrahepatic, lymph node and lung metastasis and peritoneal seeding. In two groups the growth rate of metastatic lesions following implantation was clearly higher than that of primary tumours. Chromosome analysis from locally growing tumours confirmed their morphologically human origin. An immunohistochemical study showed that implanted tumours originating from AFP-positive specimens maintained AFP expression. These results indicated that the animal models should prove valuable for developing new treatment modalities and studying the mechanism of metastasis of human HCC.

**Key words** Hepatocellular carcinoma · Metastatic models · Orthotopic implantation · Nude mice

**Abbreviation** HCC hepatocellular carcinoma · AFP  $\alpha$ -fetoprotein

### Introduction

Invasion and metastasis are the major obstacles to successful cancer treatment (Aznavoorian et al. 1993), and relevant animal models for human cancer could be very important when new therapies for human cancer are sought (Furukawa et al. 1993). However, human tumours grown subcutaneously (s.c.) in nude mice rarely metastasize, although their morphology, biology and biochemistry closely resemble those of the original tumours (Sharkey and Fogh 1984). Recently, Fidler has indicated that implanting human tumour cells orthotopically into the corresponding organ of nude mice resulted in much higher metastatic rates. For example, human colon cancer cells dissociated, grown in culture and injected into the caecum of nude mice produce tumours that eventually metastasize to the liver, demonstrating that orthotopic implantation can enhance the metastatic capability of human tumour cells in nude mice (Fidler 1990). Similar results have also been achieved for orthotopic implantation of cell lines of human lung cancer, pancreatic cancer, bladder cancer, melanoma, breast cancer, head and neck cancer and stomach cancer (Manzotti et al. 1993).

However, a recent report has indicated that cell suspensions used for orthotopic implantation may not express the full metastatic potential of the original tumour as compared with orthotopic implantation of histologically intact tissue, which avoids disruption of tumour integrity and retains native cell-to-cell interactions (Hoffman 1994). With the implanting method, models of human cancers constructed in nude mice can show the variety of clinical behaviours that occur in patients (Fu et al. 1991). Models developed by utilizing orthotopic transplantation of intact tumour tissue with resulting growth and patient-like metastasis included lung cancer (Wang et al. 1992), bladder cancer (Fu et al. 1992a), pancreatic cancer (Fu et al. 1992b), prostate

F.-X. Sun · Z.-Y. Tang (✉) · K.-D. Liu · Q. Xue · D.-M. Gao ·  
Y.-Q. Yu · X.-D. Zhou · Z.-C. Ma  
Liver Cancer Institute, Shanghai Medical University,  
Shanghai 200032, P.R. China  
Tel., Fax: 86 21 64037181

cancer (Fu et al. 1992c), ovarian cancer (Fu and Hoffman) and stomach cancer (Furukawa et al. 1993).

In this paper we describe the application of this model to human hepatocellular carcinoma (HCC), which results in extensive orthotopic growth and metastasis in nude mice. A correlation is demonstrated between different implanted specimen sources (metastatic and primary) and implantation growth in nude mice. We also discuss the possibility of constructing a highly metastatic model of human HCC in nude mice.

## Materials and methods

### Mice

Male BALB/cA nu/nu mice, 4–6 weeks old, were purchased from the Shanghai Institute of Materia Medica, Chinese Academy of Sciences, Shanghai, China.

### Surgical specimens of human HCC

Fresh surgical specimens (17 primary lesions and 13 metastatic lesions) were obtained from resected lesions of 30 patients with HCC at the Liver Cancer Institute. These surgical specimens were immediately rinsed in Hanks' balanced salt solution and transported to the laboratory as soon as possible. After necrotic tissue and non-cancerous tissue had been removed from the specimens, the remaining cancerous tissue was divided into small pieces about 2 mm in diameter.

### Implantation procedure

Tumour pieces were transplanted to the left lobe of the liver in nude mice as histologically intact tissue, using a modification of the method reported for colon cancer (Fu et al. 1991). A left upper abdominal pararectal incision was made under anaesthesia. The left lobe of the liver was exposed, then a piece of specimen was inserted and fixed into the liver. The liver was then returned to the peritoneal cavity and the abdominal wall was closed. Tumour pieces from each patient were transplanted into 3–5 mice, depending on the total volume of cancerous specimen available in each case. Mice were kept in laminar-flow cabinets under specific-pathogen-free conditions and were inspected every day.

### Evaluation of growth and metastases

Mice were sacrificed if they developed signs of distress. At autopsy, the liver, lymph nodes, lung and other organs were resected and detected by routine gross and microscopic examination. Metastases were considered to have occurred if at least one microscopic metastatic lesion was found in any part of the recipient.

### Chromosome analysis

The human origin of the tumours growing in the nude mice was confirmed by chromosome analysis. Tumour masses were finely minced and incubated for 2 h at 37°C in RPMI-1640 medium with 10% fetal calf serum (FCS) and 8 mg/ml collagenase II. The tissues were then washed repeatedly in a dish with fresh medium, and

filtered through a 100-mesh screen. The cell suspensions were incubated for 48 h at 37°C in RPMI-1640 medium supplemented with FCS, and colcemid was added at a concentration of 0.001 µg/ml 12 h before harvest. The G-banding technique was used for the analysis of karyotype (Ochi et al. 1984).

### Immunohistochemical studies

Expression of  $\alpha$ -fetoprotein (AFP) was studied by using rabbit anti-(human AFP) antibody (code A008; Dakopatts, Denmark). Tissues obtained from the mice were fixed in formalin and embedded in paraffin. Sections of 5 µm were assayed for AFP expression by immunoperoxidase staining using the avidin-biotin complex (ABC) method. Briefly, tissue sections were deparaffinized in xylene, rehydrated in graded ethanol and treated for 20 min with 0.3% H<sub>2</sub>O<sub>2</sub>/methanol to block endogenous peroxidase. The sections were incubated with 10% normal serum for 20 min and then with mAb to AFP for 1 h at 37°C and then at 4°C overnight; slides were washed for 10 min in TRIS/NaCl, and the sections incubated for 30 min with diluted biotinylated antibody solution; slides were then washed for 10 min in TRIS/NaCl and sections were incubated for 40 min with Vectastain ABC reagent; finally slides were washed in TRIS/NaCl at room temperature for 10 min. The slides were then rinsed in TRIS/NaCl/0.04% diaminobenzidine (Sigma), and 0.001% H<sub>2</sub>O<sub>2</sub> was added for 7 min to initiate the peroxidase reaction. TRIS/NaCl washes were then followed by counterstaining with haematoxylin (3 min) (Vectastain ABC Reagents and Kits, USA).

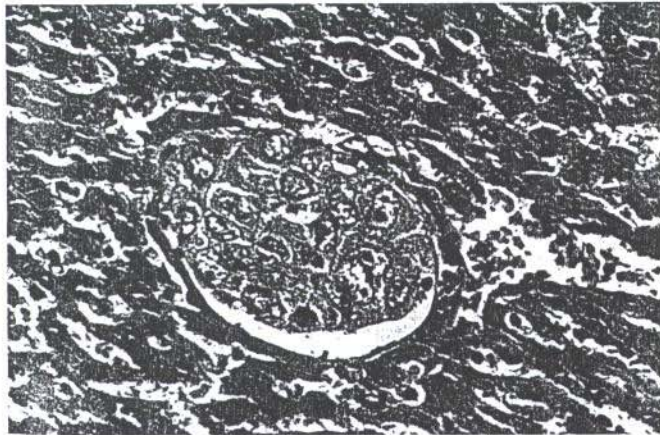
## Results

From 30 transplanted HCC specimens, including 13 metastatic lesions and 17 primary tumours, 14 gave rise to locally growing tumours in the mice, ranging in size from 1 cm to 3 cm over a period of 6–24 weeks after transplantation. Of the 13 metastatic specimens, 9 resulted in local growth in the implantation sites, whereas only 5 of the other 17 primary tumour specimens did so (Table 1). The growth rate of these metastatic lesions following transplantation was much higher than the growth of those from primary tumours in nude mice (69% and 29% respectively,  $P < 0.05$ ). Out of 14 orthotopic tumours grown in nude mice, 7 developed metastases in the animals (50% metastatic rate), but their metastatic rates showed no significant difference between two groups ( $P > 0.05$ ). The metastatic behaviours in nude mice showed regional, intrahepatic, lymph node, peritoneal and pulmonary metastasis.


Regional invasion was more frequently observed in our studies (10/14, 71.4%). When local tumours grew to 15 mm in diameter, the left upper abdominal wall and liver parenchyma were invaded, and extensive invasion of the stomach and duodenum, which often resulted in bloody ascites, was also noted. There were 4 cases of intrahepatic metastasis and liver metastases were small visible metastatic colonies, distributed around local tumours, and a few dominant multiple metastases. A lot of micrometastases in vessels of the liver could be observed by histological examination (Fig. 1). Lymph node metastasis was demonstrated in hepatic hilum,

**Table 1** Orthotopic transplantation of liver cancer: local tumour growth and metastasis in nude mice after transplantation of primary tumours and metastatic lesions.  
+ yes, - no

No. of specimens	Primary/metastatic	Local growth	Metastasis			
			Liver	Lymph-nodes	Lung	Peritoneum
1	-/+	+	-	-	-	+
2	+/-	+	+	+	-	-
3	-/+	+	+	+	-	-
4	+/-	-	-	-	-	-
5	+/-	-	-	-	-	-
6	-/+	+	-	-	-	-
7	+/-	+	+	-	-	-
8	+/-	-	-	-	-	-
9	+/-	-	-	-	-	-
10	+/-	-	-	-	-	-
11	-/+	+	-	-	-	-
12	-/+	+	+	+	+	+
13	-/+	-	-	-	-	-
14	-/+	+	-	-	-	-
15	-/+	-	-	-	-	-
16	+/-	-	-	-	-	-
17	+/-	-	-	-	-	-
18	-/+	+	-	+	-	-
19	+/-	+	-	-	-	+
20	+/-	-	-	-	-	-
21	+/-	-	-	-	-	-
22	+/-	-	-	-	-	-
23	+/-	+	-	-	-	-
24	+/-	+	-	-	-	-
25	-/+	-	-	-	-	-
26	+/-	-	-	-	-	-
27	+/-	-	-	-	-	-
28	-/+	-	-	-	-	-
29	-/+	+	-	-	-	-
30	-/+	+	-	-	-	-



**Fig. 1** Metastatic cells invade blood vessels of the liver and form micrometastases. Haematoxylin/eosin (H&E) stain  $\times 200$



**Fig. 2** Multifocal pulmonary metastases in an animal. H&E stain  $\times 200$

mesenteric and mediastinal lymph nodes. Lymph node metastases were usually obvious and visible. Out of 14 cases (from the 12th metastatic specimen), 1 developed lung metastasis that showed a few microscopic masses consisting of the metastatic cells and blood cells in the vessels (Fig. 2). When serious metastasis occurred,

micrometastases spread all through the lungs. Besides lung metastasis, intrahepatic metastasis, lymphatic metastasis and peritoneal seeding metastasis followed in 3 recipients implanted with one specimen. This specimen, following selection *in vivo* in nude mice, produced a metastatic tumour line with high invasive

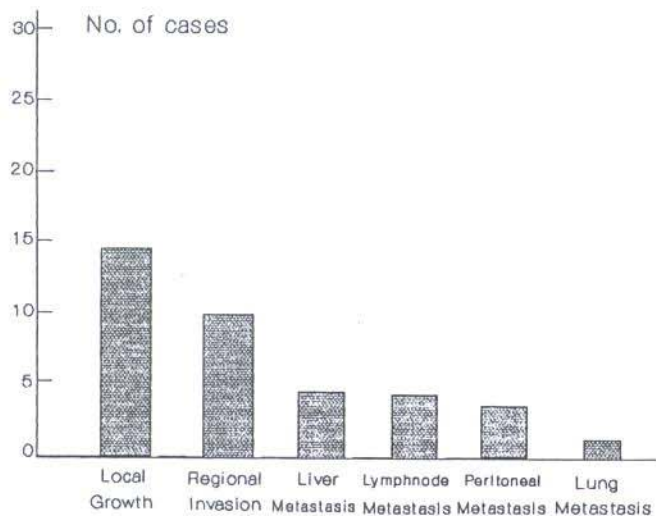


Fig. 3 Modes of growth and spread of human liver cancer specimens in nude mice after orthotopic implantation

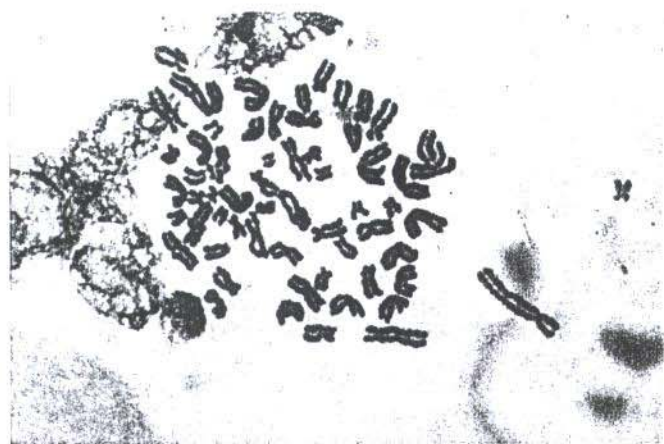

Fig. 4 Karyotype of a metaphase with 66 chromosomes from a growing tumor of the 12th specimen in an orthotopic site. The human origin was confirmed morphologically. GTB stain  $\times 1000$

and metastatic potential. A highly metastatic model of human HCC, LCI-D20 (Liver Cancer Institute; passage time: 20 days) was constructed by orthotopic transplantation of the metastatic tumour line (Sun et al. 1995). Figure 3 summarizes the frequency of occurrence of these models of tumour growth and spread in the implant model in our experiments.

The expression of AFP was detected in the locally growing transplanted tumours and in the metastatic lesions in all AFP-positive specimens. As shown in Fig. 4, chromosome analysis confirmed the human origin of the tumours grown in nude mice.

## Discussion

Subcutaneous (s.c.) tumour implantation has been a standard method for many years for establishing animal models for human cancer research (Fidler 1986, 1990). Although this model has helped us to understand the nature and therapeutic treatment of human cancer, major problems still remain unresolved. One such problem is that a tumour that is derived from a patient and subsequently put into immunodeficient animals s.c. no longer behaves as it did in the patient; i.e., although the tumour can sometimes grow s.c., it is encapsulated and usually fails to metastasize either regionally or distantly (Fidler 1990).

Recently a new strategy of what is called "orthotopic implantation" has been used for developing rodent models of metastatic human cancer (Fidler 1990; Manzotti et al. 1993). In the first generation of these models, cell lines or disaggregated cells were injected into the organ of the mouse that corresponds with the organ from which the human tumour was derived. It was shown that this method of implantation allows metastasis to occur at least in certain cases (Fidler 1990; Giavazzi et al. 1986; Beresalier et al. 1987; Morikawa et al. 1988a, b). However, the cell lines and disaggregated cells used for orthotopic implantation were obtained by disrupting the original structure of the human tumour tissue, which may lead to a change in the nature and the biological behaviour of the tumour and could be the basis of the greatly reduced metastatic rate (Fu et al. 1992a; Hoffman 1992). Hoffman et al. have, therefore, recently developed an orthotopic implant model utilizing intact tissue such as that obtained directly from surgery. This approach has yielded a high take rate and frequent metastases in many cancers. These constructed models of human cancers in nude mice can show the variety of clinical behaviours that occur in patients (Fu et al. 1991, 1992a, b, c; Wang et al. 1992).

In our study, of the surgical specimens from 30 different cases of liver cancer, implanted directly into nude mice, 14 showed local orthotopic growth and 7 specimens developed regional, lymphnode, intrahepatic and lung metastasis. These can serve as models for human liver cancer, including a model for (1) local growth, (2) regional invasion, (3) intrahepatic metastasis, (4) lymph node metastasis, (5) lung metastasis and (6) peritoneal seeding metastasis. From a clinical point of view, the most frequent metastatic sites include the hilum lymph nodes, liver, lung parenchyma and peritoneum. These sites were involved in our cases, resembling the clinical spread of liver cancer in nude mice after orthotopic transplantation of intact tissue.

The results we have presented show that histologically intact surgical specimens of liver cancer can be implanted in the liver of nude mice, grow locally, spread regionally to lymph nodes and intrahepatically,

and distally metastasize to the lung. Thus, biological behaviour of the models constructed by this implantation mimics many aspects of the natural progress in a series of typical liver cancer patients. The model may be useful in predicting drug response or the clinical course for individual patients. Spontaneous metastases of subcutaneous xerografts of human tumour in nude mice are very rare (Nakanishi et al. 1991), especially in liver cancer. Our data indicate that the metastatic rate of these tumours implanted in nude mice increased to 50% (7 of 14 cases) because orthotopic transplantation was used, demonstrating that orthotopic implantation can heighten the metastatic capability of liver cancer cells in nude mice. The tumorigenicity of various human tumours in nude mice correlates with a poor clinical outcome for the patients (Jessup et al. 1989). Neoplasms are biologically heterogeneous and consist of cells with different metastatic potentials, and the development of metastases represents the fortuitous survival and growth of a unique subpopulation of malignant cells endowed with special properties (Fidler 1990). That properties of survival and growth of metastatic cells in an ectopic environment also affect their tumorigenicity in nude mice was verified in this study. For example, in two groups, the transplantability of metastatic lesions was significantly higher than that of primary lesions. Therefore, the events of producing highly metastatic models of human cancers in nude mice can be increased by transplanting metastatic specimens. In our experiment, a metastatic line of human HCC was selected from 13 metastatic specimens and, from this metastatic line, a highly metastatic model of HCC (LCI-D20) has been constructed in nude mice. The model shows the variety of clinical behaviour that occurs in liver cancer patients (Sun et al. 1995).

When implanted specimens were AFP-positive, expression of AFP was well maintained in the locally growing orthotopically transplanted tumour and in the metastatic lesions, suggesting that the liver cancer growing and metastasizing in the nude mice resembled the original tumours removed from the patients. Our findings indicated that these mouse models retained the native structure of the liver cancer and its original antigenic phenotype, further demonstrating that this model does, indeed, resemble the natural biological behaviour of liver cancer.

Aruga et al. (1993) accidentally established a liver metastatic model of human hepatoma in nude mice by subcutaneous transplantation, but this model only had metastases in the liver and a few metastases in the spleen and lung, whereas our orthotopic metastatic models of HCC can show the clinical behaviour of patients with HCC. Thus, the above results suggest that such an animal model of individual human tumours can facilitate optimal individual therapy and the study of metastasis of human liver cancers.

**Acknowledgements** This work was partly supported by the China Medical Board of New York, grant 93-583, and a Leading Speciality Grant from the Shanghai Health Bureau.

## References

- Aruga A, Takasaki K, Hanyu F (1993) Establishment and characterization of liver metastatic model of human hepatoma in nude mice. *Int Hep Comm* 1: 138-145
- Aznavoorian S, Murphy AN, Stetler-Stevenson WG, Liotta LA (1993) Molecular aspects of tumour cell invasion and metastasis. *Cancer* 71: 1368-1383
- Beresalier RS, Raper SE, Hujanen ES, Kim YS (1987) A new animal model for human colon cancer metastasis. *Int J Cancer* 39: 625-630
- Fidler IJ (1986) Rational and methods for the use of nude mice to study the biology and therapy of human cancer metastasis. *Cancer Metastasis Rev* 5: 29-49
- Fidler IJ (1990) Critical factors in the biology of human cancer metastasis Twenty-eighth G.H.A. Clowes Memorial Award Lecture. *Cancer Res* 50: 6130-6138
- Fu X, Hoffman RM (1993) Human ovarian carcinoma metastatic models constructed in nude mice by orthotopic transplantation of histologically-intact patient specimens. *Anticancer Res* 13: 283-286
- Fu X, Besterman JM, Monosov A, Hoffman RM (1991) Models of human metastatic colon cancer in nude mice orthotopically constructed by using histologically-intact patient specimens. *Proc Natl Acad Sci USA* 88: 9345-9349
- Fu X, Theodorescu D, Kerbel RS, Hoffman RM (1992a) Extensive multi-organ metastasis following orthotopic implantation of histologically-intact human bladder carcinoma tissue in nude mice. *Int J Cancer* 49: 938-939
- Fu X, Guadagni F, Hoffman RM (1992b) A metastatic nude-mouse model of human pancreatic cancer constructed orthotopically from histologically-intact patient specimens. *Proc Natl Acad Sci USA* 89: 5645-5649
- Fu X, Herrera H, Hoffman RM (1992c) Orthotopic growth and metastasis of human prostate carcinoma in nude mice after transplantation of histologically intact tissue. *Int J Cancer* 52: 987-990
- Furukawa T, Fu X, Kubota T, Watanabe M, Kitajima M, Hoffman RM (1993) Nude mouse metastatic models of human stomach cancer constructed using orthotopic implantation of histologically intact tissue. *Cancer Res* 53: 1204-1208
- Giavazzi R, Jessup JM, Campbell DE, Walker SM, Fidler IJ (1986) Experimental nude mouse model of human colorectal cancer liver metastases. *J Natl Cancer Inst* 77: 1303-1308
- Hoffman RM (1992) Patient-like models of human cancer in mice. *Curr Perspect Mol Cell Oncol* 1: 311-326
- Hoffman RM (1994) Orthotopic is orthodox: why are orthotopic-transplant models different from all other models? *J Cell Biochem* 56: 1-4
- Jessup JM, Giavazzi R, Campbell D, Cleary KR, Morikawa K, Hostetter R, Atkinson EN, Fidler IJ (1989) Metastatic potential of human colorectal carcinomas implanted into nude mice: prediction of clinical outcome in patients operated upon cure. *Cancer Res* 49: 6906-6910
- Manzotti C, Audisio RA, Pratesi G (1993) Importance of orthotopic implantation for human tumours as model systems: relevance to metastasis and invasion. *Clin Exp Metastasis* 11: 5-14
- Morikawa K, Walker SM, Jessup JM, Fidler IJ (1988a) In vivo selection of highly metastatic cells from surgical specimens of different primary human colon carcinoma implanted into nude mice. *Cancer Res* 48: 1943-1948

- Morikawa K, Walker SM, Nakajima M, Pathak S, Jessup JM, Fidler IJ (1988b) Influence of organ environment on the growth, selection, and metastasis of human colon carcinoma cells in nude mice. *Cancer Res* 48:6863-6871
- Nakanishi H, Yasui K, Yamagata S, Shimizu S, Ando S, Hosoda S (1991) Establishment and characterization of a new spontaneous metastasis model of human gastric carcinoma in nude mice. *Jpn J Cancer Res* 82:927-933
- Ochi H, Wake N, Rao U, Takeuchi J, Slocum HK, Rustum YM, Kabakousis C, Sandberg AA (1984) Serial cytogenetic analysis of a recurrent malignant melanoma. *Cancer Genet Cytogenet* 11:175-183
- Sharkey FE and Fogh J (1984) Considerations in the use of nude mice for cancer research. 3:341-360
- Sun FX, Tang ZY, Liu KD, Ye SL, Xue Q (1995) Growth pattern and metastatic behaviour of orthotopically metastatic model of human hepatocellular carcinoma in nude mice (LCI-D20). *Nat Med J China* 75:673-675
- Wang X, Fu X, Hoffman RM (1992) A new patient-like metastatic model of human lung cancer constructed orthotopically with intact tissue via thoracostomy in immunodeficient mice. *Int J Cancer* 51:992-995